



© Arina A. Petrova¹, Natalya S. Sukortseva¹, Alexandr A. Shevalgin²,
Alim A. Nebezhev¹, Igor V. Reshetov^{1,2}

Choice of the Surgical Access for Malignant Tumors of the Central Zone of the Facial Skeleton

¹Department of Oncology, Radiotherapy and Reconstructive Surgery, I.M. Sechenov First Moscow State Medical University of the Ministry of Health of the Russia, Moscow, the Russian Federation

²Department of Oncology and Plastic surgery, FSBI Federal Scientific and Clinical Center of the Federal Medical and Biological Agency of Russia, Moscow, the Russian Federation

© А.А. Петрова¹, Н.С. Сукорцева¹, А.А. Шевалгин², А.А. Небезhev¹, И.В. Решетов^{1,2}

Выбор метода оперативного доступа к средней зоне лицевого скелета при лечении злокачественных опухолей*

¹Федеральное государственное автономное учреждение высшего образования «Первый Московский государственный медицинский университет имени И.М. Сеченова» Министерства здравоохранения Российской Федерации, Москва, Российская Федерация

²Федеральное государственное бюджетное учреждение «Федеральный научно-клинический центр специализированных видов медицинской помощи и медицинских технологий Федерального медико-биологического агентства», Москва, Российская Федерация

This review describes the issue of surgical treatment for tumors in the middle third of the facial skeleton. Given the anatomical characteristics, clinical manifestations and social significance of this area, the operation should be as radical as possible, with minimal aesthetic and functional impairment in the postoperative period, in order to improve the oncological outcome and preserve the patient's quality of life. Surgical treatment is considered the "gold standard" for the treatment of sinonasal tumors, but the introduction of new methods of local control, such as intra-arterial chemoembolization, intraoperative radiation therapy and alternative radiation therapy sources and modalities, are more evidence and are helping surgeons to reduce the morbidity of surgical treatment while maintaining its radicality. The standard traumatic approaches through the medial line of the face are still used. While endoscopic access has its advantages and limitations, it is gaining popularity for the treatment of sinonasal tumors. If the primary tumor is spread over two or more anatomical compartments, endoscopic access is not applicable. Therefore, the "dismasking" bicoronal approach can be used to reduce morbidity in the visible facial area. The "dismasking" bicoronal access provides a large surgical field, helps to adequately assess the extent of the tumor and radically removes it with surrounding healthy tissue, while preserving the integrity of the facial skin, muscles and function of the facial and other cranial nerves and critical structures. To achieve better treatment results "dismasking" bicoronal access should be considered as an alternative to standard transfacial access and endoscopic method, taking into account the indications and limitations for each patient individually.

Представленный обзор посвящен современному состоянию проблемы хирургического лечения опухолей средней трети лицевого скелета. Учитывая анатомические особенности, клиническое течение и социальное значение данной области, операция должна носить максимально радикальный характер при достижении минимального эстетического и функционального дефекта в послеоперационном периоде в целях улучшения онкологических результатов и сохранения качества жизни. Хирургическое вмешательство считается «золотым стандартом» лечения синоназальных опухолей, но внедрение новых методов локального контроля заболевания, таких как внутриартериальная химиоэмболизация, интраоперационная лучевая терапия, а также альтернативных источников и режимов лучевой терапии набирают все большую доказательную базу и способствуют снижению травматичности первичного оперативного вмешательства при сохранении радикальности операции. Наряду со стандартными травмирующими доступами, проходящими через срединную линию лица, все более популярным становится эндоскопический доступ, имеющий свои преимущества и ограничения. При распространении первичной опухоли на две и более анатомические зоны, когда эндоскопический доступ неприменим, для снижения травматизации видимой зоны лица может быть применен «демаскирующий» бикоронарный доступ, основными преимуществами которого является обеспечение широкого операционного поля, возможность адекватно оценить края опухолевого роста и радикально удалить новообразование единым блоком с включением окружающих здоровых тканей, сохранив при этом целостность кожного покрова видимой области лица, функции лицевого и других черепно-мозговых нервов и критических структур этой области. При выборе тактики оперативного вмешательства для достижения лучших результатов лечения «демаскирующий» бикоронарный доступ должен быть рассмотрен как альтернатива стандартным трансфациальным доступам и эндоскопическому методу с учетом показаний и ограничений для каждого пациента индивидуально.

Keywords: sinonasal tumor; surgery; endoscopic approach; dismasking; bicoronal access

For Citation: Arina A. Petrova, Natalya S. Sukortseva, Alexandr A. Shevalgin, Alim A. Nebezhev, Igor V. Reshetov. Choice of the surgical access for malignant tumors of the central zone of the facial skeleton. *Voprosy Onkologii = Problems in Oncology*. 2025; 71(2): 00-00. (In Rus).-DOI: 10.37469/0507-3758-2025-71-2-OF-2118

Ключевые слова: синоназальные опухоли; хирургическое лечение; эндоскопический доступ; демаскирующий доступ; бикоронарный доступ

Для цитирования: Петрова А.А., Сукорцева Н.С., Шевалгин А.А., Небежев А.А., Решетов И.В. Выбор метода оперативного доступа к средней зоне лицевого скелета при лечении злокачественных опухолей. *Вопросы онкологии*. 2025; 71(2): 00-00.-DOI: 10.37469/0507-3758-2025-71-2-OF-2118

✉ Contacts: Petrova Arina Alekseevna, aapetrova.sechenov@yandex.ru

Introduction

Malignant neoplasms of the head and neck are the 7th most common malignant disease in the world. In 2021, 580,415 primary cases of malignant neoplasms were detected in the Russian Federation, of which 1,012 were malignant tumors of the nasal cavity and paranasal sinuses (1.4 %) [1]. According to world statistics, the incidence of malignant neoplasms of the nasal cavity and paranasal sinuses is 0.556 cases per 100,000 population, which is < 5 % of all malignant neoplasms of the head and neck [2].

Due to the anatomical structure of the middle third of the facial skull, tumors in this area often have a prolonged asymptomatic clinical presentation. The clinical manifestations of the disease most often begin with non-specific symptoms such as nasal congestion, rhinorrhea, pain syndrome. If the neoplasm has already spread to the orbital cavity, for example, more specific symptoms such as exophthalmos, diplopia, decreased visual acuity [3] are present, allowing the physician to suspect the diagnosis. These clinical features determine the diagnosis of the disease in late, locally advanced stages (III–IV) in more than 80 % of cases [4, 5].

The middle third of the facial skeleton consists of the nasal cavity, the paranasal sinuses, the maxilla, the orbit and its contents, the pterygopalatine fossa, the infratemporal fossa, the parapharyngeal space and the skull base. The functional differences of these anatomical structures lead to a morphological diversity of tumors. The vestibule of the nasal cavity is lined with keratinized squamous epithelium and contains sweat and sebaceous glands and hair follicles. The squamous epithelium of the nasal vestibule at the entrance to the nasal cavity gives way to the cuboidal or columnar epithelium, which then gives way to the respiratory epithelium, which lines most of the nasal cavity and sinuses. The respiratory epithelium is a multi-row, cylindrical ciliated epithelium consisting of three main cell types: ciliated, goblet and basal cells. The olfactory region of the mucosa is located on the ethmoid bone and the upper third of the nasal septum. This type of mucosa contains olfactory nerve cells. Any of these cells can give rise to a benign, malignant or transient sinonasal tumor.

The paranasal sinuses are the main source of tumors at this site, accounting for 0.2–3 % of all tumors, and their number is increasing every year. Most commonly, these tumors arise from the epithelium of the maxillary sinuses (75–80 %), ethmoid and nasal cavities (10–15 %). The frontal and cuneiform sinuses are less commonly involved (1–2 %). Morphologically, tumors of the mid-facial region are represented by squamous cell carcinoma in 61 % of cases [6]. Malignant neoplasms in this region are less common and include adenocarcinoma (27 %), neuroendocrine carcinoma (2 %) and undifferentiated sinonasal carcinoma. Non-epithelial malignancies are less common in this region, for example, primary mucosal melanoma is only 0.03 % of all cancers, although it affects the head and neck organs in 70 % of cases [7, 8]. Esthesioneuroblastoma is a malignant neoplasm of the olfactory nerve, it occurs with a frequency of 2 to 6 % among sinonasal tumors and has a peculiar clinical course [9]. Other non-epithelial tumors occurring in the middle third of the facial skeleton include sarcomas (chondrosarcoma, fibrosarcoma, biphenotypic sarcoma, Ewing sarcoma, rhabdomyosarcoma), paraganglioma, schwannoma, NUT carcinoma and lymphomas (NK and B cell) [2, 10].

According to Russian and foreign clinical guidelines, the primary treatment for advanced sinonasal tumors is surgery followed by radiotherapy [11]. Therefore, the overall survival (OS) of patients directly depends on the margin status after surgery [12]. The likelihood of recurrence after primary treatment remains high for certain histological subtypes, and the 5-year overall survival (5-OS) rate for sinonasal malignancies varies from 20 to 70 % depending on morphology and clinical stage. The evidence base for the impact of systemic treatment of sinonasal cancer remains scarce, as the incidence of these tumors in the population is low and these malignancies are often excluded from head and neck cancer treatment trials [13]. For this reason, craniofacial resection is the ‘gold standard’ treatment for advanced tumors of the middle third of the facial skull.

Despite their low prevalence, maxillofacial tumors represent a serious problem for oncologists and maxillofacial surgeons due to the close proximity of critical and vital structures in a relatively

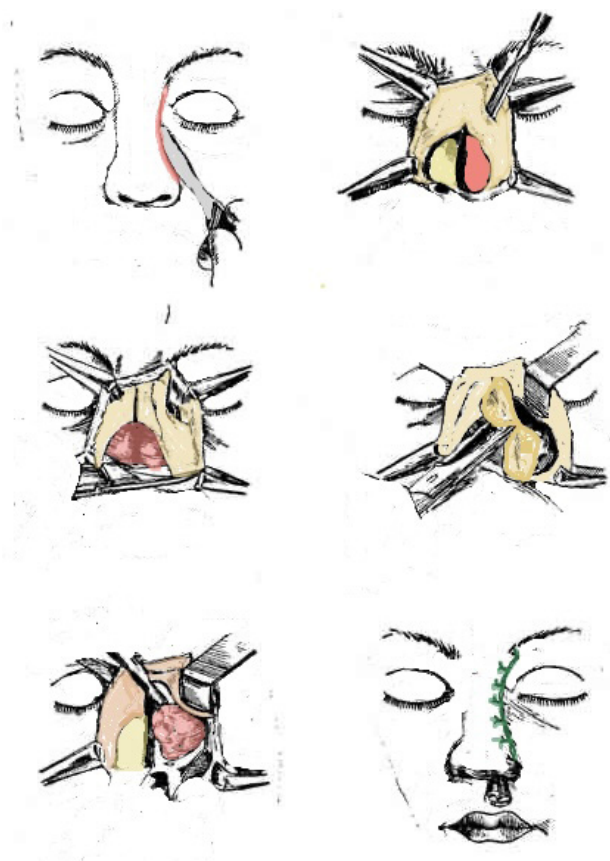


Fig. 1. Lateral rhinotomy. The transfacial incision is made along the lateral wall of the external nose. The myocutaneous flap is elevated and the maxillary osteotomy is made to access the sinus

small, confined anatomical space. The primary locally advanced process with involvement of adjacent bony and soft tissue structures makes radical surgery technically difficult. Nevertheless, the surgeon's goal would be complete tumor removal with a negative margin status and, where possible, preservation of the integrity and function of adjacent organs and neurovascular bundles. At the same time, modern treatment standards dictate the importance of both to increase OS and preserve the patient's quality of life. Rough postoperative changes in such a socially important area of the visible facial zone, which determines the individual appearance of a person, are incompatible with further successful social and psychological rehabilitation of the patient. To solve the above mentioned problems of surgical treatment of advanced tumors in the middle third of the facial skeleton, including sinonasal tumors, it is crucial to choose the best surgical approach when performing radical surgery.

Historical Standard

As mentioned above, craniofacial resection, first described in the literature by Ketcham et al in 1963, has historically been considered the "gold standard"

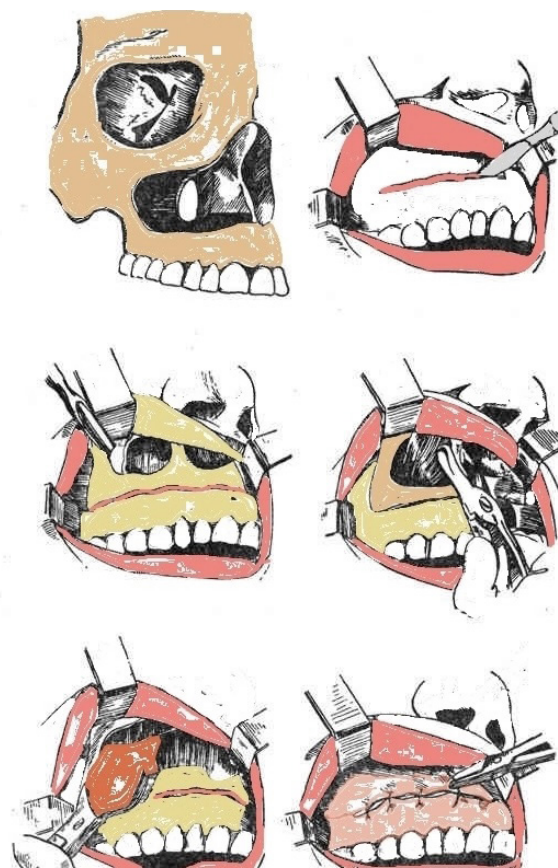


Fig. 2. Sublabial Rouge-Denker access. The incision is made 2 cm below the junction of the upper maxillary mucosa. Subsequent mucosal dissection and osteotomy provide access to the body of the maxilla. After completion of the main phase of the incision, the mucosa is closed with knot sutures

treatment for locally advanced sinonasal tumours. In 19 patients with locally advanced neoplasms of the nasal cavity, paranasal sinuses and orbit without metastatic process, en bloc tumor removal was performed via the craniofacial approach [14]. Using the technique described, the authors were able to perform radical surgery in 10 cases, increasing recurrence-free survival to 75 months for epidermoid carcinoma and 46 months for sarcoma, and improving quality of life in terms of pain relief for the patients. The combined craniofacial access described in Ketcham's paper was a coronary access with frontal flap elevation performed by a team of neurosurgeons and a Weber-Ferguson transfacial access performed by a team of oncology surgeons. The introduction of this access allowed en bloc removal of locally advanced tumors in the middle third of the facial skeleton, including those growing into the anterior fossa.

Since the last century, the standard surgical access for open craniofacial resection has been two main types of access: the lateral rhinotomy and its variants, and the Rouge-Denker sublabial access (fig. 1, 2) [15]. This access is combined with a bicoronal incision to allow greater access to the infratemporal and anterior fossa.

The lateral rhinotomy, variations of which include the Weber-Ferguson and Moore techniques, provides access to the maxillary, ethmoid and cuneiform sinuses. In combination with an additional bicoronal incision, it can be used to access the frontal sinus and anterior fossa. This technique involves a wide transfacial incision along the dorsum of the nose to the red lip border and involves all soft tissue layers of the midface. Although this approach is universally recognised as optimal, its obvious disadvantages are: a relatively limited surgical field; the inability to adequately assess the lateral limits of the tumor when it spreads laterally to the zygomatic arch, masticatory muscles and pterygopalatine region; a full-thickness incision in the central part of the face, which affects the aesthetic result in the postoperative period in the form of scarring changes in the central zone of the face [16].

The Rouge-Denker sublabial access, as well as the midfacial degloving method, opens the anterior walls of both maxillary sinuses up to the maxillary tuberosities on both sides for surgery. This access has the advantage that no incisions are made on the facial surface. However, the width of the surgical field is dramatically limited.

With the development of systemic and radiation therapy options and the introduction of reconstructive surgery into head and neck surgery, the duration and quality of life of patients with advanced tumors has increased significantly. However, standard open craniofacial resection is considered a mutilating procedure and carries certain risks of postoperative complications, including wound infection, diplopia, osteomyelitis, and gross aesthetic defects of the facial region [17].

Endoscopic approach

The development of endoscopic techniques, improved preoperative planning and imaging capabilities, and additional options for adjuvant radiotherapy over the past two decades have naturally increased the role of minimally invasive techniques in both general surgery and the treatment of sinonasal tumours. Endoscopic surgery is an operator-dependent technique with a long learning curve, and sufficient equipment is often only available in large medical centres. This explains the fact that the main body of information available in the world literature is mainly represented by small, single-centre, non-randomised studies, often describing the experience of a single surgeon [17]. However, the number of such data is increasing every year [18].

Endoscopic access to the structures of the middle third of the facial skeleton and the base of the skull is provided transnasally and transmaxillary by the Denker approach. In the context of reducing morbidity through endoscopic procedures, this

involves the removal of the lesion by debulking. This technique does not correspond to the main principles of oncological surgery - ablative and antitumoral. However, there are studies that show comparable results for some morphological subtypes of sinonasal tumors, regardless of open en bloc tumor removal or endoscopic debulking method [19–22]. Localized tumors, T1–T2 stage, have also been reported to be an indication for endoscopic procedure [23].

Over the past decade, there has been a trend towards expanding the indications for minimally invasive techniques. Husain et al 2019 analyzed the treatment of 10,193 patients with sinonasal cancer (SNC) of all stages treated between 2010 and 2015 based on national data. They found that open surgery was performed in 71.9 % of SNC cases [24]. This was more common in patients with advanced disease (T3–T4). Minimally invasive surgery was performed in 28.1 %, mostly in patients with early-stage disease (T1–T2). Data from recent systematic reviews and meta-analyses reflect the increasing popularity of endoscopic techniques among surgeons and their use in later stages of disease [25, 26].

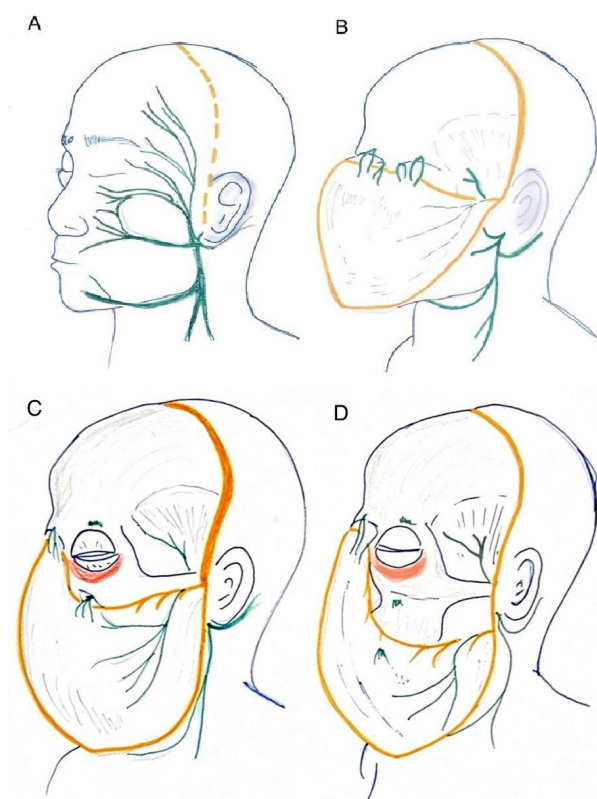


Fig. 3. (A) Scheme of facial nerve anatomy and facial flap procedure. The facial nerve runs below the external auditory canal and covers the entire face. A coronal skin incision can be made maximally at the level of the tragus. (B) The coronal skin flap is elevated together with the facial nerves and muscles inferior to the orbit. (C) An additional unilateral circumcylpebral incision allows the skin graft to be separated from the orbital structures and elevated inferiorly. The infraorbital nerve is not divided. (D) Resection of the infraorbital nerve allows further exposure. The nasal bone and superior part of the maxilla can be exposed

The expansion of adjuvant radiotherapy options, the introduction of intensity-modulated radiotherapy (IMRT), volume-modulated radiotherapy (VMAT) and the latest radiation sources (proton and carbon therapy) into clinical practice have allowed oncologists to achieve greater local control of SNC after surgery, which is naturally leading to a revolution in its surgical principles. For example, Liu et al. demonstrate comparable long-term oncological outcomes - 5-year overall survival (OS), progression-free survival (PFS) and local recurrence rate (LRR) - in the single-centre retrospective study of patients with advanced SNC treated with open and endoscopic techniques from 1998 to 2016 [18]. In the open surgery group, 45 patients underwent IMRT with a mean dose of 65 Gy after open craniofacial resection using standard transfacial accesses (lateral rhinotomy, Weber-Ferguson access) in the adjuvant mode. In the endoscopic group, 45 patients underwent surgery including debulking followed by IMRT with a mean dose of 69 Gy. Thus, by increasing the aggressiveness of radiotherapy, the authors were able to achieve 5-year OS, PFS and LRR in the endoscopic group comparable to standard treatment: 69.9, 58.6, 24.5 % in the endoscopic group and 64.6, 54.4, 31.8 % in the open surgery group.

Despite the fact that more and more such data are accumulating in the world literature, it is not possible to extrapolate the results of such a study to the whole population due to the following factors: the literature data on this topic are mostly of a low level of evidence (single-center, non-randomized studies); the shorter follow-up period compared to open surgery; the more careful selection of patients for endoscopic intervention (early stages and more convenient localizations); the possible tendency to refuse publication in case of negative results [17].

Due to the lack of strong evidence for the superiority of endoscopic access in the surgical management of locally advanced SNC, head and neck surgeons remain faced with the important problem of reducing treatment-related morbidity while achieving maximum radicality of surgery. Clear indications for the use of different techniques are needed to improve oncological outcomes and patient quality of life.

“Dismasking” bicorony access

A person's social standing is greatly influenced by the condition of the middle third of the facial skeleton. Its appearance directly affects the patient's quality of life and further psychological and social rehabilitation. The surgical approach to cancer treatment in this region should allow the surgeon to assess the true margins of cancer invasion intraoperatively — to achieve R0 status after surgery

with negative margins and inclusion of the adjacent compartment [27], and to minimize aesthetic defect without leaving disfiguring scars and deformities [28]. The choice of surgical access is an important component of the treatment strategy for locally advanced tumors of the craniofacial region.

The coronary access was first described in 1907 by Hamley and Keyton for the treatment of the anterior fossa and its contents [29]. The coronal approach became popular in maxillofacial surgery after it was used by Tessier in 1971 to perform the Le Fort I and Le Fort II osteotomies [30]. The coronal access in this case consists of a hairline incision between the apexes of both ears. The soft tissues of the frontal region are then elevated up to the upper rim of the eye. From the resulting access, an osteotomy is performed.

In 1993, Tajima et al first described a method of “dismasking” bicoronal access to structures of the middle third of the facial skeleton and skull base [31]. In the technique described, the bicoronal approach is combined with an eyelid incision. Depending on the extent of tumor invasion, the lifting of the facial soft tissues can be continued down to the inferior edge of the maxilla. The described approach provides a wide surgical field for radical en-bloc removal of advanced tumors without leaving visible scars on the face or damaging motor nerves (fig. 3).

The use of a “dismasking” access is justified by the peculiarities of the facial soft tissue anatomy and the permanence of the facial nerve location relative to the superficial and deep muscular-aponeurotic systems [32]. The facial soft tissue flap is supplied by the anterior and parietal branches of the superficial temporal artery and the supraorbital bundle. The superficial temporal artery lies adjacent to and supplies blood to the parieto-temporal fascia [32, 33]. Sensory innervation in the medial forehead region comes from the supraorbital and supraorbital bundles; the lateral region receives sensory innervation from the auriculotemporal and zygomaticofacial nerves. The supraorbital neurovascular bundle exits the cranial cavity through a hole or node in the superior-medial area of the oculomotor arch and runs along the surface of the frontalis muscle [34]. The temporal branch of the facial nerve supplies motor innervation to the frontalis muscle and is responsible for raising the eyebrow. After leaving the parotid salivary gland, the temporal branch, together with the anterior branch of the superficial temporal artery, passes over the zygomatic arch under the temporoparietal fascia or superficial temporal fascia. The distal part of the temporal branch remains under the temporoparietal fascia until it penetrates the frontalis muscle 1–2 cm above the superior eye margin [32]. A loose avascular layer of fat tissue lies between the temporoparietal fascia

with the adjacent temporal branch and the deep temporal fascia, making it ideal for dissection and soft tissue lifting [32, 35]. Deeper is the layer of deep temporal fascia, which continues into the periosteum above the temporal line. In the area of the upper ocular margin, the deep fascia divides into two layers, with the superficial temporal fat running between them. The deep sheet covers the temporal muscle and continues to the medial surface of the zygomatic arch. The superficial sheet of the deep temporal fascia continues to the lateral part of the zygomatic arch, where it is immediately adjacent to the superficial fascia and the temporal branch of the facial nerve [32, 33].

Depending on the location and extent of the primary tumor, various modifications of the “dismasking” bicoronal approach can be used. In order to reduce morbidity, shorten operative time and improve post-operative aesthetic outcomes, the bicoronal approach could be extended to unilateral dissection of facial soft tissues, an incision framing one eye with dissection of the supraorbital and infraorbital bundles. This is relevant for tumor masses originating from the maxillary sinus, orbit, infratemporal region and pterygopalatine fossa [16, 36].

When the tumor is centrally located, such as in massive nasal lesions, Kishimoto et al. suggest the technique of elevating the nasal bones and frontal processes of the maxilla as part of the elevated facial soft tissues to provide optimal access to the nasal cavity [37]. During tissue repositioning after the main surgical procedure, bone and cartilage are fixed with plates or monofilaments.

If it is necessary to access such deep anatomical structures as the oropharyngeal space or the pterygopalatine fossa, additional osteotomies may be performed in the area of the frontal-mandibular junction, at the base of the zygomatic bone, and in the area of the zygomaticomandibular junction [38]. To prevent osteonecrosis and osteomyelitis in the postoperative period, the blood supply to the bone flap is maintained at the expense of the adjacent masseter muscle. In the case of a problematic tumor mass location with involvement of the main cervical vessels, as in the case of Masuda et al, a combination of a bicoronal “dismasking” approach with a transcervical approach is applicable.

The use of the “dismasking” bicoronal access is described in the literature for the treatment of both malignant and benign neoplasms of the nasal cavity, paranasal sinuses, orbit, skull base, wing fossa, subclavian region and parapharyngeal space, for the treatment of recurrent abscesses and other maxillofacial pathologies of the areas described above, including in children [39, 40].

The postoperative complications described in the literature (oedema of the soft tissues of the face, lagophthalmos, decreased sensation in the forehead

area) resolve within 3–6 months without the need for further intervention. The literature also describes methods to prevent the development of lagophthalmos, which is usually associated with dehydration of the circular oculi muscle during surgery. Application of gauze soaked in physiological solution allows to reduce the degree of its dysfunction in the postoperative period [41].

Obvious limitations to the use of the technique described are the spread of the tumor into the skin and subcutaneous fat, if such a surgical approach is not radical.

Discussion

Despite their morphological diversity, all sinonasal tumours are characterized by a long asymptomatic course and primary diagnosis at a late stage. This behaviour is explained by the anatomical features of the midfacial skull: hollow paranasal sinuses and the close proximity of vital structures such as vascular and nerve trunks and the skull base with its contents.

Surgery combined with radiotherapy remains the mainstay of treatment for sinonasal tumors. Clean resection margins significantly improve patient OS. For sinonasal lesions, surgery with macroscopically positive resection margins does not affect OS compared to nonsurgical treatment [12]. To achieve radicality and reduce the traumatic nature of surgery, the role of intraoperative radiotherapy is currently being debated [42–44]. The advantage of this approach is the elimination of the time lag between surgery and adjuvant radiotherapy, the accuracy and precision of targeting the radiation source to the removed tumor bed and ‘doubtful’ resection margins, and the potential reduction in treatment toxicity due to the physical ability to mobilize surrounding structures and organs in the area at risk [45]. However, there is currently a lack of evidence to support the advantages of this approach over the standard strategy. Intra-arterial selective or super-selective chemoperfusion combined with RADPLAT regimen of radiotherapy is another potential method to reduce the aggressiveness of surgical treatment or in some cases is its alternative [46, 47]. However, the role of surgery remains important, which is supported by the data showing a significant increase in OS after RADPLAT in cases where salvage surgery was performed [48].

The anatomical features of SNC described above make surgical treatment difficult. In order to perform radical surgery and remove the entire tumor mass, the surgeon needs a large surgical field while minimizing damage to critical facial structures (facial and other cranial nerves, major orbital vessels, cranial bones). An additional reconstructive stage is

Criteria for selecting a surgical access to the middle third of the facial skeleton and skull base tumors

Criteria	Open access	Endoscopic access
Morphology	Squamous cell cancer, adenocarcinoma, undifferentiated sinonasal carcinoma, sarcoma	Benign tumors, esthesioneuroblastoma, mucosal melanoma, adenoid cystic carcinoma
Local extensions	Hard palate, alveolar ridge, orbital floor, skin, subcutaneous fat, anterior maxillary periosteum, nasal bone, the frontal process of the maxillary bone, buccal and masticatory space, extraconal fat, ocular muscles, frontal sinus	Nasal septum, ethmoidal complex, sphenoidal roof and floor, pterygopalatinum fossa, infratemporal fossa, upper parapharyngeal space, medial orbit wall, minimal invasion of extraconal fat, bone structures of the skull base, adjacent dura mater
Reconstructive option	Free and local vascularized flaps	Vascularized nasoseptal flap, collagen matrix, gelatinous sponge, autologous fat graft
Tumour removal technique	En bloc	Debulking

often required to compensate for a scaffold and a separate function after mutilating surgery to eliminate the resulting defect. Another peculiarity of this area is its undisputed social and psychological role in human life. At the present stage of development, the aim of oncological treatment is not only to increase life expectancy, but also to maintain and improve its quality. These characteristics should be taken into account when planning the operation and choosing the optimal surgical approach.

Open craniofacial resection has historically been the ‘gold standard’ surgical treatment for malignant SNC, with a 5-year survival rate of up to 51 % [2]. The standard techniques for such surgery are the Moore transfacial access, Weber-Ferguson access and Weber-Ferguson modifications, which are traumatic and leave visible postoperative changes [18]. Since the end of the twentieth century, surgery in this area has been increasingly performed using endoscopic access. The endoscopic approach is less traumatic, but it has its limitations, such as significant spread of tumor masses, involvement of vascular, nerve and bone structures, poorly differentiated tumors and certain locations of tumor resection. For example, according to Ferrari et al, open surgery is always required when the hard palate, alveolar process and body of the maxilla, orbital walls, soft tissues of the middle third of the face, cheek and masseter space are involved, while in other cases the possibility of endoscopic technique is discussed. Endoscopic and open surgery should complement each other’s capabilities, not conflict [18].

An alternative to transfacial and endoscopic approaches is the “dismasking” bicoronal approach, first described by Tajima et al in 1993 for the removal of tumours in the middle third of the facial skeleton [31]. The technique of this access involves a bicoronal incision 2 to 3 cm beyond the hairline, an eye-framing incision, and subsequent full-layer lifting of the facial soft tissues from top to bottom. The so-called “face mask” includes the skin, subcutaneous fatty tissue, muscular-aponeurotic systems, mimic muscles and nerve bundles, which allows the craniofacial complex to be exposed without

damaging the facial nerve, leaving facial scars only around the eyelids, as in blepharoplasty. This approach allows the complete removal of volumetric neoplasms of the base of the skull, reaching the nasal cavity, the orbit and the upper jaw, without causing gross cosmetic defects and without damaging the facial nerve and, in some cases, the optic nerve. The technique can be modified according to the area of interest and the extent of the procedure, as mentioned above.

However, due to the difficulty of the procedure, the need for microsurgical skills and the use of appropriate tools and techniques, and the potential for postoperative complications, this approach has not been widely used and is now quite rare.

Attempts are currently being made to develop protocols for the choice of surgical access in the treatment of tumors of the middle third of the facial skeleton and the base of the skull, particularly between endoscopic and open surgery. According to various authors, contraindications to endoscopic surgery include tumor extension into the soft tissues of the face or brain, gross involvement of the soft or hard palate, frontal sinus and lacrimal duct [15], lateral wall of the orbit, which can lead to orbital extrusion, destruction of the maxillary bone and the need for open access reconstruction [17]. The choice of surgical access may depend on the morphological pattern of the lesion: in cases where the oncological outcome depends directly on the margin status — squamous cell carcinoma, adenocarcinoma, undifferentiated sinonasal carcinoma, sarcoma — open surgery is preferred [12, 15]. In the treatment of esthesioneuroblastoma, mucosal melanoma and adenoid cystic carcinoma, the oncological results after endoscopic surgery are comparable to those after open surgery, with a lower morbidity [15].

The main criterion for choosing between the classic transfacial and bicoronal “dismasking” approaches is the extent of tumour extension into the facial soft tissues. If the skin, subcutaneous fat, mimic muscles and nerve structures are involved, the “dismasking” access loses its relevance. Accord-

ing to Yano et al, in a patient with a history of skull base and orbital surgery, the aesthetic results after a “dismasking” access remain unsatisfactory in 40 % due to facial asymmetry, and therefore this factor can be considered a limitation for bicoronal access [49]. In real clinical practice, the experience of the surgical team and the level of equipment available at the health centre are of paramount importance when choosing a surgical tactic (table).

Conclusion

As the most visible part of the human body, the midface has a complex anatomical structure and its condition has a direct impact on a person’s social and psychological well-being. Although malignant neoplasms in this area are rare, surgical treatment is usually crippling because the diagnosis is generally made at a late stage. The aim of surgical treatment of malignant neoplasms of this area is to achieve maximum radicality with minimum aesthetic and functional compromise. The choice of the optimal surgical approach should serve as a potential solution to this problem. “Dismasking” bicoronal access may be an alternative to standard transfacial and endoscopic approaches in cases of significant spread of tumor disease in the middle third of the facial skeleton and should be considered when choosing surgical treatment tactics, which require its improvement to achieve better treatment outcomes.

Conflict of interest

The authors declare no conflict of interest.

Funding

The study was performed without external funding.

Authors’ contributions

The authors declare the compliance of their authorship according to the international ICMJE criteria.

Petrova A.A. — reviewed the publications on the topic of the article, drafted the article, performed technical editing, organized the references.

Sukortseva N.S. — reviewed the publications on the topic of the article, drafted the article.

Shevalgin A.A. — reviewed the publications on the topic of the article, drafted the article.

Nebezhev A.A. — reviewed the publications on the topic of the article, performed technical editing.

Reshetov I.V. — suggested the idea for the publication, performed scientific editing.

All authors have approved the final version of the paper before publication, agreed to assume responsibility for all aspects of the paper, implying proper review and resolution of issues related to the accuracy or integrity of any part of the article.

REFERENCES

- Kaprin A.D., Starinskij V.V., Shahzadova A.O. Sostoyanie onkologicheskoy pomoshchi naseleniyu Rossii v 2021 godu. Moscow: P.A. Herzen MNIOI — a branch of FGBU “NMRC Radiology” of the Ministry of Health of Russia. 2021: 239(ill.).-URL: <https://oncology-association.ru/wp-content/uploads/2022/05/sostoyanie-onkologicheskoy-pomoshchi-naseleniyu-rossii-v-2021-godu.pdf?ysclid=m334t3k2o1814738027>.
- Thawani R., Kim M.S., Arastu A., et al. The contemporary management of cancers of the sinonasal tract in adults. *CA Cancer J Clin.* 2023; 73: 72-112.-DOI: doi.org/10.3322/caac.21752.
- Taylor M.A., Saba N.F. Cancer of the paranasal sinuses. *Hematol Oncol Clin North Am.* 2021; 35: 949-62.-DOI: [10.1016/j.hoc.2021.05.006](https://doi.org/10.1016/j.hoc.2021.05.006).
- Turri-Zanoni M., Gravante G., Castelnovo P. Molecular biomarkers in sinonasal cancers: new frontiers in diagnosis and treatment. *Curr Oncol Rep.* 2022; 24: 55-67.-DOI: [10.1007/s11912-021-01154-3](https://doi.org/10.1007/s11912-021-01154-3).
- Sakata K., Maeda A., Rikimaru H., et al. Advantage of extended craniofacial resection for advanced malignant tumors of the nasal cavity and paranasal sinuses: long-term outcome and surgical management. *World Neurosurg.* 2016; 89: 240-54.-DOI: [10.1016/j.wneu.2016.02.019](https://doi.org/10.1016/j.wneu.2016.02.019).
- Ackall F.Y., Issa K., Barak I., et al. Survival outcomes in sinonasal poorly differentiated squamous cell carcinoma. *Laryngoscope.* 2021; 131: E1040-8.-DOI: [10.1002/lary.29090](https://doi.org/10.1002/lary.29090).
- López F., Rodrigo J.P., Cardesa A., et al. Update on primary head and neck mucosal melanoma. *Head Neck.* 2016; 38: 147-55.-DOI: [10.1002/hed.23872](https://doi.org/10.1002/hed.23872).
- Abt N.B., Miller L.E., Mokhtari T.E., et al. Nasal and paranasal sinus mucosal melanoma: Long-term survival outcomes and prognostic factors. *Am J Otolaryngol - Head Neck Med Surg.* 2021; 42.-DOI: [10.1016/j.amjoto.2021.103070](https://doi.org/10.1016/j.amjoto.2021.103070).
- Limaem F., Das J.M. Esthesioneuroblastoma. StatPearls. Treasure Island (FL): StatPearls Publishing. 2023.
- Haerle S.K., Gullane P.J., Witterick I.J., et al. Sinonasal carcinomas. epidemiology, pathology, and management. *Neurosurg Clin N Am.* 2013; 24: 39-49.-DOI: [10.1016/j.nec.2012.08.004](https://doi.org/10.1016/j.nec.2012.08.004).
- Caudell J.J., Gillison M.L., Maghami E., et al. NCCN Guidelines® Insights: head and neck cancers, version 1.2022. *JNCCN.* 2022; 20: 224-34.-DOI: [10.6004/jnccn.2022.0016](https://doi.org/10.6004/jnccn.2022.0016).
- Jafari A., Shen S.A., Qualliotine J.R., et al. Impact of margin status on survival after surgery for sinonasal squamous cell carcinoma. *Int Forum Allergy Rhinol.* 2019; 9: 1205-11.-DOI: [10.1002/alr.22415](https://doi.org/10.1002/alr.22415).
- Hermesen M.A., Bossi P., Franchi A., Lechner M. Sinonasal cancer: improving classification, stratification and therapeutic options. *Cancers (Basel).* 2023; 15.-DOI: [10.3390/cancers15061675](https://doi.org/10.3390/cancers15061675).
- Ketcham A.S., Wilkins R.H., Van Buren J.M., Smith R.R. A combined intracranial facial approach to the paranasal sinuses. *Am J Surg.* 1963; 106: 698-703.-DOI: [10.1016/0002-9610\(63\)90387-8](https://doi.org/10.1016/0002-9610(63)90387-8).
- López F., Shah J.P., Beitler J.J., et al. The selective role of open and endoscopic approaches for sinonasal malignant tumours. *Adv Ther.* 2022; 39: 2379-97.-DOI: [10.1007/s12325-022-02080-x](https://doi.org/10.1007/s12325-022-02080-x).
- Polyakov A.P., Reshetov I. V., Zaytsev A.M., et al. A surgical approach as dysmasking in patients with malignant tumors of the paranasal sinuses and skull base. *Head and Neck Tumors (HNT).* 2015; 5: 16.-DOI: [10.17650/2222-1468-2015-5-3-16-23](https://doi.org/10.17650/2222-1468-2015-5-3-16-23).
- Albonette-Felicio T., Rangel G.G., Martínez-Pérez R., et al. Surgical management of anterior skull-base malignancies (endoscopic vs. craniofacial resection). *J Neurooncol.* 2020; 150: 429-36.-DOI: [10.1007/s11060-020-03413-y](https://doi.org/10.1007/s11060-020-03413-y).

18. Liu Q., Huang X., Chen X., et al. Long-term outcomes of endoscopic resection versus open surgery for locally advanced sinonasal malignancies in combination with radiotherapy. *J Neurol Surg B Skull Base*. 2022; 85: 28-37.-DOI: 10.1055/a-1980-8567.
19. Povolotskiy R., Farber N.I., Bavier R.D., et al. Endoscopic versus open resection of non-squamous cell carcinoma sinonasal malignancies. *Laryngoscope*. 2020; 130: 1872-6.-DOI: 10.1002/lary.28270.
20. Barinsky G.L., Azmy M.C., Kilic S., et al. Comparison of open and endoscopic approaches in the resection of esthesioneuroblastoma. *Annals of Otolaryngology & Laryngology*. 2021; 130: 136-41.-DOI: 10.1177/0003489420939582.
21. Kashiwazaki R., Turner M.T., Geltzeiler M., et al. The endoscopic endonasal approach for sinonasal and nasopharyngeal adenoid cystic carcinoma. *Laryngoscope*. 2020; 130: 1414-21.-DOI: 10.1002/lary.28100.
22. Farber N.I., Bavier R.D., Crippen M.M., et al. Comparing endoscopic resection and open resection for management of sinonasal mucosal melanoma. *Int Forum Allergy Rhinol*. 2019; 9: 1492-8.-DOI: 10.1002/alr.22422.
23. Jiang S., Fan R., Zhang H., et al. Outcomes of endoscopic and open resection of sinonasal malignancies: a systematic review and meta-analysis. *Braz J Otorhinolaryngol*. 2022; 88: 19-31.-DOI: 10.1016/j.bjorl.2021.06.004.
24. Husain Q., Joshi R.R., Cracchiolo J.R., et al. Surgical management patterns of sinonasal malignancy: a population-based study. *J Neurol Surg B Skull Base*. 2019; 80: 371-9.-DOI: 10.1055/S-0038-1675233.
25. Jiang S., Fan R., Zhang H., et al. Outcomes of endoscopic and open resection of sinonasal malignancies: a systematic review and meta-analysis. *Braz J Otorhinolaryngol*. 2022; 88: 19-31.-DOI: 10.1016/j.bjorl.2021.06.004.
26. Lu V.M., Ravindran K., Phan K., et al. Surgical outcomes of endoscopic versus open resection for primary sinonasal malignancy: a meta-analysis. *Am J Rhinol Allergy*. 2019; 33: 608-16.-DOI: 10.1177/1945892419856976.
27. Har-El G. Anterior craniofacial resection without facial skin incisions - A review. *Otolaryngology - Head and Neck Surgery*. 2004; 130: 780-7.-DOI: 10.1016/j.otohns.2004.01.015.
28. Jaju H. Unfavourable results in skull base surgery. *Indian Journal of Plastic Surgery*. 2013; 46: 239-46.-DOI: 10.4103/0970-0358.118599.
29. Hartley F., Kenyon Jh. Experiences in cerebral surgery. *Ann Surg*. 1907; 45: 481-530.-DOI: 10.1097/0000658-190704000-00001.
30. Tessier P. The definitive plastic surgical treatment of the severe facial deformities of craniofacial dysostosis. *Plast Reconstr Surg*. 1971; 48: 419-42.-DOI: 10.1097/00006534-197111000-00002.
31. Tajima S., Tanaka Y., Imai K., et al. Extended coronal flap - "dismasking flap" for craniofacial and skull base surgery. *Bull Osaka Med Sch*. 1993; 39: 1-8.
32. Frodel J.L., Marentette L.J. The coronal approach: anatomic and technical considerations and morbidity. *Archives of Otolaryngology - Head and Neck Surgery*. 1993; 119: 201-7.-DOI: 10.1001/archotol.1993.01880140091014.
33. Sykes J.M., Riedler K.L., Cotofana S., Palhazi P. Superficial and deep facial anatomy and its implications for rhytidectomy. *Facial Plast Surg Clin North Am*. 2020; 28: 243-51.-DOI: 10.1016/j.fsc.2020.03.005.
34. Higashino T., Okazaki M., Mori H., et al. Microanatomy of sensory nerves in the upper eyelid: A cadaveric anatomical study. *Plast Reconstr Surg*. 2018; 142: 345-53.-DOI: 10.1097/PRS.0000000000004554.
35. Hwang K. Surgical anatomy of the facial nerve relating to facial rejuvenation surgery. *Journal of Craniofacial Surgery*. 2014; 25: 1476-81.-DOI: 10.1097/SCS.0000000000000577.
36. Koda H., Tsunoda A., Iida H., et al. Facial dismasking flap for removal of tumors in the craniofacial region. *Laryngoscope*. 2007; 117: 1533-8.-DOI: 10.1097/MLG.0b013e31806dd040.
37. Kishimoto S., Tsunoda A., Koda H. 2010 Nasal downward swing approach coupled with the facial dismasking flap. *Auris Nasus Larynx*. 2010; 37: 217-9.-DOI: 10.1016/j.anl.2009.07.005.
38. Masuda M., Fukushima J., Fujimura A., Uryu H. Combined transcervical and orbitozygomatic approach for the removal of a nasopharyngeal adenocarcinoma. *Auris Nasus Larynx*. 2016; 43: 192-6.-DOI: 10.1016/j.anl.2015.06.006.
39. Ishii Y., Yano T., Ito O. Use of the facial dismasking flap approach for surgical treatment of a multifocal craniofacial abscess. *Arch Plast Surg*. 2018; 45: 271-4.-DOI: 10.5999/aps.2017.00969.
40. Ohno K., Tsunoda A., Shirakura S., et al. The approaches and outcomes of skull base surgery for pediatric sarcoma after initial therapy. *Auris Nasus Larynx*. 2011; 38: 208-14.-DOI: 10.1016/j.anl.2010.08.005.
41. Fujimoto T., Imai K., Takahashi M., et al. Retrospective assessment of the dismasking flap procedure as a craniofacial approach. *J Neurosurg Pediatr*. 2011; 7: 345-50.-DOI: 10.3171/2011.1.PEDS10271.
42. Kyrgias G., Hajioannou J., Tolia M., et al. Intraoperative radiation therapy (IORT) in head and neck cancer: A systematic review. *Medicine (US)*. 2016; 95: e5035.-DOI: 10.1097/MD.0000000000005035.
43. Chiodo C., Gros S., Emami B., et al. Intraoperative radiation therapy for locally advanced and recurrent head and neck cancer. *Mol Clin Oncol*. 2022; 17.-DOI: 10.3892/mco.2022.2591.
44. Sarria G.R., Petrova V., Wenz F., et al. Intraoperative radiotherapy with low energy x-rays for primary and recurrent soft-tissue sarcomas. *Radiation Oncology*. 2020; 15.-DOI: 10.1186/s13014-020-01559-7.
45. Villafuerte C.V.L., Ylanan A.M.D., Wong H.V.T., et al. Systematic review of intraoperative radiation therapy for head and neck cancer. *Ecancermedicalscience*. 2022; 16.-DOI: 10.3332/ecancer.2022.1488.
46. Homma A., Mikami M., Matsuura K., et al. Dose-finding and efficacy confirmation trial of the superselective intra-arterial infusion of cisplatin and concomitant radiation therapy for locally advanced maxillary sinus cancer (JCOG1212): Results of the efficacy confirmation phase in patients with T4aN0M0. *International Journal of Radiation Oncology*Biophysics*. 2024; 118: 1271-81.-DOI: 10.1016/j.ijrobp.2023.11.031.
47. Ikeda M., Suzuki M., Matsuzuka T., et al. Neoadjuvant super-selective intra-arterial cisplatin chemoradiotherapy combined with surgery in patients with T4 squamous cell carcinoma of the maxillary sinus. *Journal of Oral and Maxillofacial Surgery*. 2022; 80: 1445-50.-DOI: 10.1016/j.joms.2022.04.014.
48. Tsushima N., Kano S., Suzuki T., et al. Title: Salvage surgery improves the treatment outcome of patients with residual/recurrent maxillary sinus cancer after superselective intra-arterial cisplatin infusion with concomitant radiation therapy. n.d.
49. Yano T., Okazaki M., Tanaka K., et al. Indication for and limitation of the facial dismasking flap approach for skull base surgery to achieve the best esthetical and functional results. *Ann Plast Surg*. 2017; 78: 49-53.-DOI: 10.1097/SAP.0000000000000662.

Authors' Information / ORCID ID

Arina A. Petrova / ORCID ID: <https://orcid.org/0000-0003-4258-6196>; SPIN: 7547-5303.

Natalya S. Sukortseva / ORCID ID: <https://orcid.org/0000-0002-7704-1658>; SPIN: 1728-6019.

Alexandr A. Shevalgin / ORCID ID: <https://orcid.org/0000-00020-7045-5540>; SPIN: 4353-5478.

Alim A. Nebezhev / ORCID ID: <https://orcid.org/0009-0003-6557-5841>; SPIN: 4125-0091.

Igor V. Reshetov / ORCID ID: <https://orcid.org/0000-0002-0909-6278>; SPIN: 3845-6604.

