

© Yukihiro Hama, Etsuko Tate

## Salvage Adaptive Radiotherapy for Locally Advanced Breast Cancer with Axillary Lymph Node Involvement after Failure of Neoadjuvant Chemotherapy

Edogawa Hospital, Tokyo, Japan

© Ю. Хама, Э. Тамэ

### Адаптивная высокодозная лучевая терапия для лечения местнораспространенного рака молочной железы с вовлечением аксиллярных лимфатических узлов после неудачной неoadъювантной химиотерапии

Больница Эдогава, Токио, Япония

**Introduction.** Neoadjuvant chemotherapy (NAC) is the standard treatment for locally advanced triple-negative breast cancer (TNBC), but when ineffective, surgical resection becomes difficult.

**Case Description.** A 53-year-old woman was referred after failure of NAC for locally advanced TNBC on the right side with axillary lymph node involvement. After second-line NAC, the breast cancer was unresectable and high-dose adaptive radiotherapy was performed. The initial plan was to treat both the breast cancer and the axillary lymph node metastasis with rotational intensity-modulated radiation therapy (IMRT) with simultaneously integrated boost (IMRT-SIB). After the initial plan was completed, an adaptive plan was created to treat the remaining breast cancer and axillary lymph nodes. One year after radiotherapy, both the breast cancer and the axillary lymph node metastases disappeared with no serious adverse events.

**Conclusion.** High-dose adaptive rotational IMRT-SIB may be an effective salvage treatment for locally advanced TNBC after failure of NAC.

**Keywords:** breast neoplasms; neoadjuvant therapy; image-guided radiotherapy; intensity-modulated radiotherapy

**For Citation:** Y. Hama, M.D., Ph.D., E. Tate. Salvage adaptive radiotherapy for locally advanced breast cancer with axillary lymph node involvement after failure of neoadjuvant chemotherapy. *Voprosy Onkologii = Problems in Oncology*. 2025; 71(2): 00-00.-DOI: 10.37469/0507-3758-2025-71-2-OF-2190.

✉ Contacts: Yukihiro Hama, yjhama2005@yahoo.co.jp  
✉ Контакты: Юкихи́ро Хама, yjhama2005@yahoo.co.jp

**Введение.** Неoadъювантная химиотерапия является стандартным методом лечения местнораспространенного трижды негативного рака молочной железы (ТН РМЖ), однако при ее неэффективности проведение хирургической резекции становится затруднительным.

**Описание случая.** 53-летняя женщина была направлена после неудачной неoadъювантной химиотерапии для лечения местнораспространенного ТН РМЖ с правой стороны с вовлечением аксиллярных лимфатических узлов. После второй линии неoadъювантной химиотерапии присутствовали противопоказания для хирургического лечения РМЖ, и была проведена высокодозная адаптивная лучевая терапия. Изначально планировалось лечить РМЖ и метастазы аксиллярных лимфатических узлов с помощью лучевой терапии с модулированной интенсивностью (IMRT) с симультанным интегрированным бустом (IMRT-SIB). После завершения первоначального этапа был создан адаптивный план для лечения оставшегося РМЖ и аксиллярных лимфатических узлов. Через год после лучевой терапии РМЖ и метастазы аксиллярных лимфатических узлов исчезли без серьезных побочных эффектов.

**Заключение.** Лучевая терапия с модулированной интенсивностью с симультанным интегрированным бустом (IMRT-SIB) может быть эффективным методом лечения местнораспространенного ТН РМЖ после неудачной неoadъювантной химиотерапии.

**Ключевые слова:** новообразования молочной железы; неoadъювантная терапия; лучевая терапия с визуальным контролем; лучевая терапия с модулированной интенсивностью

## Introduction

Neoadjuvant chemotherapy (NAC) is a standard treatment approach for locally advanced triple-negative breast cancer (TNBC) to increase the likelihood of complete resection, allow less invasive

surgery and provide valuable information about the tumor's response to chemotherapy [1]. However, if chemotherapy is not effective, surgical resection will be difficult and there is a risk that curative treatment will not be achieved. Here, we report a case of locally advanced TNBC with axillary lymph

node involvement successfully treated with high-dose adaptive radiotherapy using helical tomotherapy after failure of NAC.

### Case Report

A 53-year-old woman was referred to our department after failure of NAC for locally advanced TNBC on the right side. The patient had undergone a left mastectomy for early breast cancer 10 years earlier, followed by adjuvant chemotherapy with doxorubicin cyclophosphamide, and docetaxel, and has had no recurrence since then. This time she developed stage IIB (cT2 N1 M0, AJCC, 8th ed.) TNBC on the right side and underwent NAC with 5-fluorouracil, epirubicin and cyclophosphamide. Despite the combination chemotherapy, the tumor grew slowly, so it was changed to docetaxel and bevacitumab. Contrary to the second line NAC, the tumor continued to grow and the patient was referred to our department for radiotherapy.

Whole-body F18 fluorodeoxyglucose (FDG) positron emission tomography (PET)/computed tomography (CT) revealed a hypermetabolic tumor in the right breast and ipsilateral axillary lymph nodes (Figures 1a and 1b), but there were no distant metastases. Contrast-enhanced CT showed strong rim enhancement of the right breast cancer (Figure 1c), but only two swollen axillary lymph nodes (Figure 1d). Contrast-enhanced MRI after gadolinium-based contrast agents showed an irregularly shaped breast cancer in the right breast with heterogeneous rim enhancement (Figure 1e). Axillary lymph nodes

showed heterogeneous enhancement (Figure 1f). Chest wall involvement was suspected on physical examination and MRI, surgical resection was considered impossible, and she was to undergo radiotherapy. As the patient had no distant metastases and no complications, locoregional tumor control had the potential to not only prolong survival but also improve quality of life. High-dose adaptive radiotherapy with helical tomotherapy was performed to control the right breast cancer and ipsilateral axillary lymph node metastases.

This treatment protocol was approved by the institutional review board of TECC (Ref. RO201932), and all procedures were conducted in accordance with the 2013 revision of the Declaration of Helsinki. The patient signed informed consent for the publication of their data.

#### *Radiotherapy treatment planning*

The treatment protocol consisted of two courses of radiotherapy: the initial course consisted of rotational intensity-modulated radiation therapy (IMRT) with simultaneous integrated boost (SIB) using helical tomotherapy (TomoTherapy®, Accuray, Madison, Wisconsin, United States). Gross tumor volume (GTV) was the visible extent of the right breast cancer and involved axillary lymph nodes as determined by contrast-enhanced CT and/or post-gadolinium T1-weighted MRI. The entire breast and axillary lymph nodes on the right side were included in the clinical target volume (CTV). Planning target volumes (PTVs) were created by adding 2–3 mm three-dimensional margins for GTV (PTVg) and CTV (PTVc). The prescribed doses for

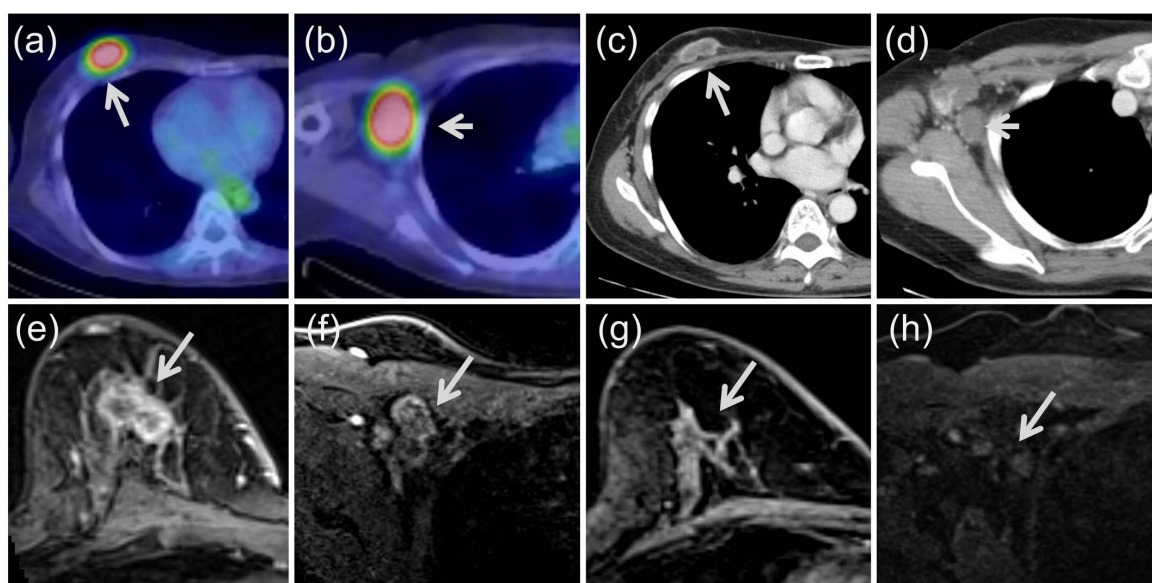


Fig. 1. F18 fluorodeoxyglucose (FDG) positron emission tomography (PET) /computed tomography (CT), contrast-enhanced CT, and post-gadolinium T1-weighted magnetic resonance imaging (MRI). Hypermetabolic breast tumor (arrow) (a) and axillary lymph nodes (arrow) (b) were detected by FDG-PET/CT. Contrast-enhanced CT showed strong rim enhancement of the right breast cancer (arrow) (c), but minimal enhancement of the axillary lymph nodes (arrow) (d). Contrast-enhanced MRI showed an irregularly shaped breast cancer with heterogeneous rim enhancement (arrow) (e). Chest wall involvement was suspected due to adjacent tissue changes between the tumor and the chest wall. Axillary lymph nodes showed heterogeneous enhancement (arrow) (f). Contrast-enhanced MRI one year after high-dose adaptive radiotherapy showed no residual breast cancer (g) or axillary lymph node involvement (h)

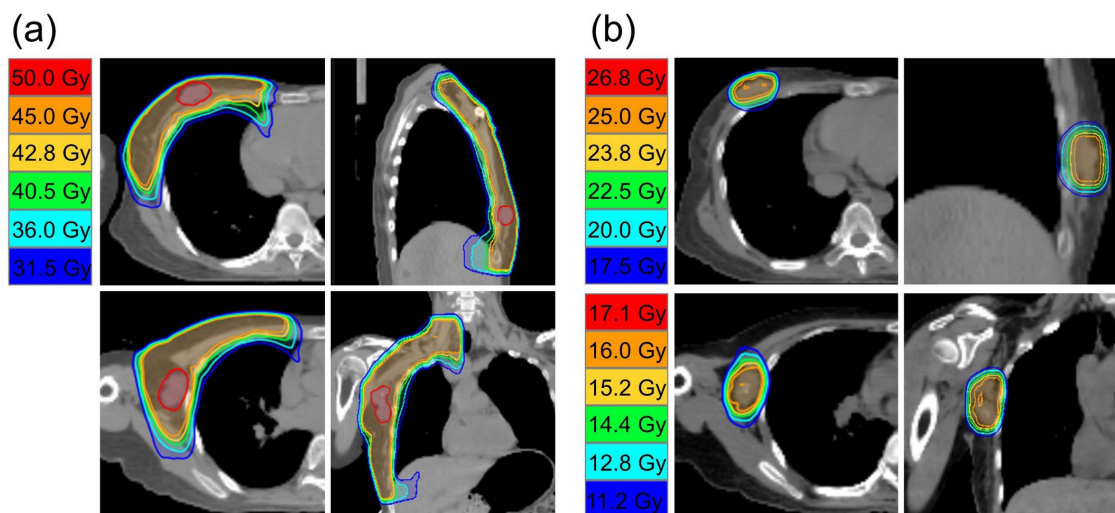


Fig. 2. Isodose lines of high-dose adaptive radiotherapy for the treatment of right breast cancer and axillary lymph node metastases  
(a) Initial radiotherapy treatment planning. Upper left: Transverse section of right breast carcinoma. Upper right: Sagittal section of right breast carcinoma. Bottom left: Transverse section of right axillary lymph nodes. Bottom right: Coronal section of right axillary lymph nodes.  
(b) Adaptive radiotherapy treatment planning. Upper left: Transverse section of right breast carcinoma. Upper right: Sagittal section of right breast carcinoma. Bottom left: Transverse section of right axillary lymph nodes. Bottom right: Coronal section of right axillary lymph node

PTVg and PTVc were 50 and 45 Gy, respectively, in 25 fractions over 5 weeks (Figure 2a). Rotational IMRT with SIB was performed using helical tomotherapy. Immediately after the initial course, radiotherapy treatment planning was performed in the same manner as the initial planning (adaptive plan), and GTVs of the right breast cancer (GTVb) and metastatic axillary lymph nodes (GTVa) were determined. By adding 2–3 mm three-dimensional margins, PTVs were created for GTVb (PTVb) and GTVa (PTVa). In adaptive radiotherapy planning, the prescribed dose was 25 Gy in 8 fractions for PTVb and 16 Gy in 8 fractions for PTVa (Figure 2b).

#### *Treatment Outcome*

There was no grade 2 or higher adverse events during or after radiotherapy. Grade 1 dermatitis developed during radiotherapy, but gradually resolved within one month after completion of radiotherapy. On follow-up MRI, the right breast cancer and axillary lymph node metastasis gradually shrank and disappeared one year after radiotherapy (Figures 1g and h). MRI 18 months after radiotherapy showed no locoregional recurrence, but systemic metastases including liver metastases had developed. She was treated with systemic chemotherapy, including gemcitabine, eribulin and TS-1, but died of systemic metastases two years after radiotherapy. Until her death, there was no evidence of recurrence in the areas treated with high-dose adaptive radiotherapy.

#### **Discussion**

To our knowledge, this is the first report of successful local salvage radiotherapy for TNBC after failure of second-line NAC. NAC is usually effective

in shrinking the tumor, but 20–30 % of patients are refractory to NAC and the tumor progresses despite NAC [2, 3]. If the tumor is refractory to NAC and continues to grow, it can be surgically removed if resectable, but if not, radical local treatment may be difficult. This case suggests the efficacy and safety of high-dose adaptive rotational IMRT-SIB for refractory TNBC with axillary lymph node involvement.

There are several advantages to this case report. First, by combining the advantages of both rotational IMRT-SIB and adaptive radiotherapy techniques, the appropriate dose of radiation could be delivered while minimizing toxicity to normal tissues. After the initial plan, the GTVs of the breast cancer and axillary lymph nodes shrank, so the GTVs in the adaptive plan became smaller, allowing the PTVs to be reduced. As a result, we believe that the radiation dose to normal tissue could be reduced. Second, this case report is the first to demonstrate that both breast cancer and axillary lymph node metastases can be controlled with radiotherapy alone. Further studies are warranted to confirm the feasibility and efficacy of high-dose adaptive IMRT-SIB for locally advanced breast cancer with axillary lymph node involvement.

There are several limitations to this case report. First, the treatment period is as long as 7 weeks. Since radiotherapy does not immediately shrink tumors, the time spent in the initial plan is considered necessary to reduce PTVs in the adaptive plan. Second, once first-line NAC was ineffective, it may have been better to undergo surgical resection without trying second-line NAC. However, at the end of first-line NAC, the breast cancer had invaded just above the chest wall and was considered unresectable.

## Conclusion

In conclusion, a single case report cannot be generalized to other cases without further scientific verification, but high-dose adaptive rotational IMRT-SIB can control both breast cancer and axillary lymph node metastases without serious adverse events.

### *Conflict of interest*

The authors declare no conflict of interest.

### *Funding*

The study was performed without external funding.

Compliance with patient rights

The study was carried out in accordance with the WMA Helsinki Declaration as amended in 2013. The patient gave written informed consent to the publication of his data.

### *Authors' contributions*

All authors made a substantial contribution to the conception of the work, acquisition, analysis, interpretation of data for

the work, drafting and revising the work, final approval of the version to be published and agree to be accountable for all aspects of the work.

## REFERENCES

1. Lin Y.Y., Gao H.F., Yang X., et al. Neoadjuvant therapy in triple-negative breast cancer: A systematic review and network meta-analysis. *Breast.* 2022; 66: 126-135.-DOI: 10.1016/j.breast.2022.08.006.
2. Samiei S., Simons J.M., Engelen S.M.E., et al. Axillary pathologic complete response after neoadjuvant systemic therapy by breast cancer subtype in patients with initially clinically node-positive disease: a systematic review and meta-analysis. *JAMA Surg.* 2021; 156(6): e210891.-DOI: 10.1001/jamasurg.2021.0891.
3. Li Y., Zhang H., Merkher Y., et al. Recent advances in therapeutic strategies for triple-negative breast cancer. *J Hematol Oncol.* 2022; 15(1).-DOI: 10.1186/s13045-022-01341-0.

Received / 25.10.2024

Reviewed / 19.11.2024

## Author Information / ORCID ID

Yukihiro Hama / ORCID ID: [https://orcid.org/ 0000-0002-2845-6603](https://orcid.org/0000-0002-2845-6603).

Etsuko Tate / ORCID ID: [https://orcid.org/ 0000-0002-2380-2802](https://orcid.org/0000-0002-2380-2802).

